

識別番号・報告回数	報告日	第一報入手日 2010年2月3日	新医薬品等の区分 該当なし	厚生労働省処理欄
一般的名称 ①②③乾燥抗 HBs 人免疫グロブリン ④⑤ポリエチレングリコール処理抗 HBs 人免疫グロブリン	研究報告の 公表状況	Haemophilia 2010: 1-9	公表国 イギリス	
販売名 (企業名) ①ヘプスリン筋注用 200 単位 (ベネシス) ②ヘプスリン筋注用 1000 単位 (ベネシス) ③ヘプスリン (ベネシス) ④ヘプスリン IH 静注 1000 単位 (ベネシス) ⑤静注用ヘプスリン-IH (ベネシス)				
研究報告の 概要	英国プール血漿由来濃縮因子製剤によって 1980~2001 年の間に出血障害の治療を行った全ての英国の患者は vCJD 感染リスクが増加した可能性のあることを告知されている。我々は、vCJD のリスクが高いと考えられる 17 人の神経学的に asymptomatic な血友病患者に関連したプロテアーゼ耐性プリオン (PrP <sup>Sc</sup> ) の検出について報告する。11 の剖検および 7 の生検材料から PrP <sup>Sc</sup> を分析した。脾臓サンプルのひとつはウェスタンブロット分析で PrP <sup>Sc</sup> 陽性であった。73 歳の患者からのこの組織は、神経症状はなかったが、プリオン蛋白遺伝子のコドン 129 はメチオニン/バリンのヘテロ型であった。彼は vCJD 感染ドナーからのドネーションを含むプール血漿から製造された第 VIII 濃縮因子 9000 単位以上および vCJD 感染ドナーからのドネーションを含むかわからない 400,000 単位の投与を受けた。彼は 14 ユニットの赤血球製剤も投与された、そしていくつかの外科的処置及び侵襲的な内視鏡的処置を受けていた。食事、手術、内視鏡、輸血そして英国製のプラズマ由来製剤を投与されたことを通しての曝露の相対的なリスクの評価において、この患者にもっともありそうな感染経路は英国製のプラズマ製剤を投与されたことであると示唆された。			使用上の注意記載状況・ その他参考事項等 代表としてヘプスリン IH 静注 1000 単位の記載を示す。 2. 重要な基本的注意 (1) 略 (2) 現在までに本剤の投与により変異型クロイツフェルト・ヤコブ病 (vCJD) 等が伝播したとの報告はない。しかしながら、製造工程において異常プリオンを低減し得るとの報告があるものの、理論的な vCJD 等の伝播のリスクを完全には排除できないので、投与の際には患者への説明を十分行い、治療上の必要性を十分検討の上投与すること。
報告企業の意見	今後の対応 本報告は本剤の安全性に影響を与えないと考えるので、特段の措置はとらない。			
英国プール血漿由来濃縮因子製剤を投与された血友病患者の vCJD 感染リスクが増加している可能性があることより、血友病患者の生体サンプルからプロテアーゼ耐性プリオン (PrP <sup>Sc</sup> ) の検出を試みたところ、73 歳の患者脾臓サンプルから PrP <sup>Sc</sup> が検出された。この患者のプリオン蛋白遺伝子のコドン 129 はメチオニン/バリンのヘテロ型であり、最もありそうな感染経路は英国製のプラズマ製剤であったとする報告である。血漿分画製剤は理論的な vCJD 伝播リスクを完全には排除できないため、投与の際には患者への説明が必要である旨を 2003 年 5 月から添付文書に記載している。2009 年 2 月 17 日、英国健康保護庁 (HPA) は vCJD に感染した供血者の血漿が含まれる原料から製造された第 VIII 因子製剤の投与経験のある血友病患者一名から、vCJD 異常プリオン蛋白が検出されたと発表した。弊社の原料血漿採取国である日本及び米国では、欧州滞在歴のある献 (供) 血希望者を一定の基準で除外し、また国内での BSE の発生数も少数であるため、原料血漿中に異常型プリオン蛋白が混入するリスクは 1999 年以前の英国に比べて極めて低いと考える。また、製造工程においてプリオンが低減される可能性を検討するための実験を継続して進めているところである。				

26

ヘプスリン

# Haemophilia

Haemophilia (2010), 1-9

ORIGINAL ARTICLE

## Variant CJD infection in the spleen of a neurologically asymptomatic UK adult patient with haemophilia

A. PEDDEN\*, L. MCCARDLE\*, M. W. HEAD\*, S. LOVE,† H. J. T. WARD,‡ H. J. T. WARD,§ S. N. COUSENS,† D. M. KEELING,§ G. C. M. MILLAR,¶ F. G. H. HILL\* and J. W. HONDSIDE\*  
\*National Centre for Inherited Blood Disorders, University of Edinburgh, Edinburgh; †Department of Neuro-pathology, Frenchay Hospital, Bristol; ‡London School of Hygiene and Tropical Medicine, London; §Oxford Haemophilia and Thrombosis Centre, Churchill Hospital, Oxford; ¶Department of Haematology, Imperial College London, London; and \*\*Department of Haematology, Birmingham Children's Hospital, Birmingham, UK

**Summary.** All UK patients with bleeding disorders treated with any UK-sourced pooled factor concentrates between 1980 and 2001 have been informed that they may be at an increased risk of infection with variant Creutzfeldt-Jakob disease (vCJD). We describe a study to detect disease-associated, protease-resistant prion protein (PrP<sup>Sc</sup>) in 17 neurologically asymptomatic patients with haemophilia considered to be at increased risk of vCJD. Materials from 11 autopsy and seven biopsy cases were analysed for PrP<sup>Sc</sup>. The tissues available from each case were variable, ranging from a single biopsy sample to a wide range of autopsy tissues. A single specimen from the spleen of one autopsy case gave a strong positive result on repeated testing for PrP<sup>Sc</sup> by Western blot analysis. This tissue came from a 73-year-old male patient with no history of neurological

disease, who was heterozygous (methionine/valine) at codon 129 in the prion protein gene. He had received over 9000 units of factor VIII concentrate prepared from plasma pools known to include donations from a vCJD-infected donor, and some 400 000 units not known to include donations from vCJD-infected donors. He had also received 14 units of red blood cells and had undergone several surgical and invasive endoscopic procedures. Estimates of the relative risks of exposure through diet, surgery, endoscopy, blood transfusion and receipt of UK-sourced plasma products suggest that by far the most likely route of infection in this patient was receipt of UK plasma products.

**Keywords:** haemophilia, plasma, prion protein, spleen, vCJD

### Introduction

Variant Creutzfeldt-Jakob disease (vCJD) was identified in the UK in 1996 [1] and subsequently shown to be caused by a transmissible agent with identical properties to the bovine spongiform encephalopathy (BSE) agent [2,3], most likely as a consequence of consumption of BSE-contaminated meat products [4]. Variant CJD represents the only known example of a human prion disease caused by exposure to an

infectious prion agent from a non-human source. It is also unique in that the transmissible agent is detectable in a much wider tissue distribution than is the case for other forms of human prion disease. Both infectivity and the protease-resistant form of disease-associated prion protein (PrP<sup>Sc</sup>) are readily detectable in a range of tissues apart from that of the central nervous system in vCJD, particularly in lymphoid tissues and the peripheral nervous system, albeit at lower levels than in the central nervous system [5,6].

Since 2004, four instances of vCJD infection (three clinical cases, one asymptomatic) in the UK have been associated with the transfusion of non-leucodepleted packed red cells from asymptomatic donors who subsequently died from vCJD [7-10]. The National Blood Authorities in the UK have taken a

Correspondence: Prof. James W. Honside, National Creutzfeldt-Jakob Disease Surveillance Unit, University of Edinburgh, Western General Hospital, Edinburgh EH4 2XU, UK.  
Tel.: +44 131 537 3109; fax: +44 131 343 1404;  
e-mail: james.honside@ed.ac.uk  
Accepted after revision 29 November 2009



number of steps to reduce the likelihood of secondary transmission of vCJD by blood components [11]. It is known that plasma donations from asymptomatic individuals infected with vCJD have also contributed to some batches of pooled clotting factor concentrate (termed 'vCJD-implicated batches'). The potential vCJD infectivity of these batches has been estimated by the UK CJD Incidents Panel (CJDIP) based on findings from a risk assessment commissioned by the Department of Health (DH) [12], together with batch-specific manufacturing data. Variant CJD-implicated batches of clotting factor concentrates factor VIII (FVIII) and IX were assessed to be likely to carry sufficient levels of vCJD infectivity to warrant the implementation of public health measures in recipients to minimize the possible risk of onward transmission [12]. A public health notification exercise of patients with bleeding disorders was conducted in 2004 by the Health Protection Agency and Scottish Centre for Infection and Environmental Health on behalf of the UK Departments of Health, at which time it was considered likely that further batches of UK-sourced plasma products would become implicated as future cases of vCJD arose [13]. Therefore, on the advice of the UK Haemophilia Centre Doctors' Organisation (UKHCDO), all patients with bleeding disorders who had been treated with any UK-sourced pooled factor concentrates between 1980 and 2001 were informed that they may be at an increased risk of infection with vCJD and were required to take measures to prevent the possibility of secondary spread of infection. This inclusive 'population' approach was endorsed by the CJDIP, DH and the Haemophilia Society.

To date, 170 cases of vCJD have been identified in the UK, including the three clinical cases in which infection is likely to have been transmitted by non-leucodepleted packed red cells transfused from asymptomatic donors who subsequently died from vCJD [7,9,10]. The annual incidence and death rate for vCJD have both declined in UK over the past few years, but the prevalence of vCJD infection in the UK remains uncertain. A retrospective study to detect disease-associated prion protein in paraffin-embedded sections of tonsil and appendix tissue indicated that the prevalence of vCJD infection might be higher than the current number of clinical cases recorded would suggest, with three positive cases being found in 12 674 tissue samples studied, giving an estimated prevalence rate of 237 vCJD infections per million in the UK population (although with wide confidence intervals) [14,15]. Further investigations on a large series of tonsil samples found a prevalence of disease-associated prion protein in tonsils from a 1961–1995

combined birth cohort of 0/32 661 with a 95% confidence interval of 0–113 per million [16]. In the 1961–1985 cohort, the prevalence of zero with a 95% confidence interval of 0–289 per million was lower than, but still consistent with, the results of the previous survey of tonsil and appendix tissues by Hilton *et al.* [14]. The prevalence of vCJD infection in the general UK population could therefore be around 1 in 10 000, based on an approximate average value between the results of these studies [14,16,17].

To date, no case of vCJD has been identified in any recipient of UK-sourced plasma products. In 2001 DH commissioned and funded a project to undertake active surveillance of UK patients with haemophilia for the possibility of vCJD infection. This study included the prospective and retrospective analysis of lymphoid tissues and brain tissue in biopsy material and/or autopsy material for the presence of the PrP<sup>res</sup> isoform characteristic of vCJD.

We report the laboratory findings in this study, demonstrating for the first time the presence of PrP<sup>res</sup> in the spleen of a UK adult haemophilic patient who at the time of death had no neurological signs or symptoms attributable to vCJD.

## Materials and methods

### Collection of tissue samples

Ethical approval was obtained for the project entitled 'Surveillance of new variant CJD-UKHCDO' (MREC/01/2/11) and the study was administered through the UKHCDO. All haemophilic patients undergoing surgical procedures involving the central nervous system and lymphoid tissue (including tonsil, lymph nodes and spleen) were encouraged to participate in the study. This applied only to patients who were to undergo surgical biopsy or resection of relevant tissues for medical reasons and was therefore opportunistic. Consent was obtained from patients for the analysis of biopsy samples and from relatives of the patient for autopsy tissues following the death of a patient undergoing either a hospital or Coroner's autopsy.

### Cases and tissue specimens

Material from 11 autopsy cases and seven biopsy cases from 17 patients had tissue samples submitted to the National CJD Surveillance Unit for investigation. One patient had biopsy samples submitted on two occasions, and another patient had both biopsy and autopsy materials examined. The number of tissues

available from each case was variable, ranging from single lymphoid tissue samples from living patients to a wide range of autopsy tissues (brain, tonsil, spleen, lymph node, appendix) in others. The samples were analysed in this study by a combination of Western blotting, paraffin-embedded tissue (PET) blotting and immunohistochemistry for disease-associated, protease-resistant prion protein (PrP<sup>res</sup>). Cases of clinically suspected CJD that were given an alternative final pathological diagnosis were used as negative controls, as they lack PrP<sup>res</sup> in the brain and peripheral tissues. Ethical approval for the acquisition and use of this autopsy material for research on transmissible spongiform encephalopathies in the National CJD Surveillance Unit brain bank is covered by LREC 2000/4/157 (JWI). The polymorphic status of codon 129 of the prion protein gene (PRNP) of each case was determined by restriction fragment length polymorphism as described previously [18].

### NaPTA precipitation/Western blot analysis for PrP<sup>res</sup>

Frozen central nervous system (cerebral frontal cortex, cerebellum, spinal cord) and lymphoreticular (spleen, tonsil, appendix) tissues (when available) from cases in this study and from vCJD and non-CJD control patients were homogenized to 10% (w/v) in 2% sarkosyl/PBS using the FastPrep™ instrument (Anachem, Cambridge, UK) and 500 µL samples of this homogenate were analysed by sodium phosphotungstic acid precipitation followed by high-sensitivity Western blotting (NaPTA/WB), as described previously [8,19,20]. At least four samples of spleen and other lymphoid tissues (when available) were studied.

### Criteria for assigning positives

Samples of frozen brain (frontal cortex) and spleen from non-CJD neurological control patients were available for use as negative controls in the Western blots in this study. As a positive control in the NaPTA/WB analyses of either central nervous system tissue or lymphoreticular tissue, 10% (w/v) vCJD brain homogenate (3 µL) was diluted into 500 µL of a 10% (w/v) homogenate of either brain or spleen tissue from a non-CJD control patient. These spiked homogenates were then diluted with a further 500 µL of 2% sarkosyl/PBS as described in the standard protocol used for all the test samples [8]. Samples of tissue from haemophilic patients in this study were assessed by comparison with positive and negative control samples run on the same gel. The following criteria were established before interpreting the results: a positive result was assigned if at least two bands were

observed to co-migrate with the corresponding PrP<sup>res</sup> bands in the positive control and no bands were seen in the lane containing non-CJD control sample, after maximum exposure to HyperFilm ECL (GE Healthcare Life Sciences, Buckinghamshire, UK).

### Centrifugal concentration/Western blotting

A number of samples of tissue homogenate prepared in 2% sarkosyl/PBS as described above were re-analysed using the centrifugal concentration/Western blot method described by us previously [6].

### Densitometric analysis of PrP<sup>res</sup> levels and glycoform ratios

For densitometric analysis, immunoblot images were scanned using a Bio-Rad GS-800 Densitometer and images were analysed and processed with QUANTITY ONE™ software (Bio-Rad, Hertfordshire, UK). Immunoblot images were included in the densitometric analysis if all three bands (di-, mono- and unglycosylated) were in the linear range.

### Immunohistochemistry and PET blotting

Paraffin-embedded tissue blot analysis was carried out as described by us previously [21], using a modified version of the method of Schulz-Shaeffer *et al.* [22]. Immunohistochemistry for disease-associated prion protein was performed using a panel of four different anti-prion protein antibodies as previously described [21].

## Results

### Biochemical analysis

The high-sensitivity Western blot (NaPTA/WB) analyses were conducted on receipt of tissue and were subject to the availability of frozen tissue specimens, which varied between patients (Table 1). One sample of spleen out of the initial four tested from one of these patients gave a very strongly positive signal for PrP<sup>res</sup> producing a poorly resolved smear, but with the highest densities in the region of the immunoblot typical for authentic PrP<sup>res</sup>. A smaller volume of the positive homogenate (50 µL rather than 500 µL) was re-analysed by NaPTA/WB in order to obtain better resolution of the immunoreactive bands, and a positive signal was confirmed according to our criteria (Fig. 1). The glycoform ratio of this positive sample was consistent with vCJD, showing a pre-dominance of the diglycosylated form of PrP<sup>res</sup>.

Table 1. Summary of frozen tissue samples analysed by NaPTA/WB for PrP<sup>res</sup>

Case number (PRNP codon 129)	Tonsil	Spleen	Lymph node	Appendix	Brain	Bone marrow	Gut
1 (MV)	-	-	-	-	0/9	-	-
2 (MV)	-	0/4	0/3	0/4	0/8	-	-
3 (MV)	0/4	0/12	0/4	-	0/12	-	-
4 (MM)	-	-	0/4	-	0/8	-	-
5 (MM)	-	-	-	-	0/8	-	-
6 (VV)	-	0/3	-	0/4	0/14	0/4	0/8
7 (MM)	0/3	0/3	-	0/3	0/3	-	-
8 (MM)	-	-	-	-	0/16	-	-
9 (MV)	-	1/26	0/2	-	0/11	-	-
10 (MM)	-	0/4	0/4	-	0/8	-	-

Depending on availability a minimum of four samples were tested from the tissue listed above. The results are given as the number of PrP<sup>res</sup> positive samples as a proportion of the total number of independent samples tested for each tissue specimen.

A dash (-) indicates that no samples were available for analysis; M, methionine; V, valine; PrP<sup>res</sup>, protease resistant prion protein; NaPTA/WB, sodium phosphotungstic acid precipitation/Western blotting.

The remaining 100 µL aliquot of this homogenate was analysed by the centrifugal concentration/Western blotting protocol and was again strongly positive (data not shown). Densitometry was used to compare the total signal (of all three PrP<sup>res</sup> bands) with a dilution series of PrP<sup>res</sup> samples from vCJD brain run in parallel with this and the previous sample. This analysis indicated that the level of PrP<sup>res</sup> in this spleen sample was 3–5% of that found in vCJD brain.

NaPTA/WB analysis of a further 22 samples taken from the available spleen tissue from this case failed to show any evidence of PrP<sup>res</sup> (Table 1). Exhaustive immunohistochemical and PET blot analysis of this

tissue was similarly negative and NaPTA/WB, immunohistochemistry and PET blotting all failed to detect the presence of PrP<sup>res</sup> in lymph node, frontal cortex or cerebellum in this case (Table 1). All other tissues from the remaining cases were negative by each of the methods used.

To make a more quantitative assessment of the glycoform ratio in the positive specimen, we again used densitometry. The glycoform ratio of the specimen positive by NaPTA/WB mapped close to, but at the extreme diglycosylated side of the area defined by Western blot analysis of vCJD brain tissue, including vCJD brain tissue 'spiked' into negative control spleen and analysed by NaPTA/WB (Fig. 2). The glycoform ratio of this positive specimen was also more predominantly diglycosylated than the samples of vCJD spleen PrP<sup>res</sup> used as positive controls in this study.

#### Genetic analysis

The results of the PRNP codon 129 analysis on each of the eight cases studied are included in Table 1. The case containing PrP<sup>res</sup> in the spleen was heterozygous (methionine/valine) at this codon.

#### Immunohistochemistry and PET blotting

Immunohistochemistry and PET blot analysis on all the PET blocks in this study were negative in all cases, including the case in which PrP<sup>res</sup> was detected biochemically in the spleen.

#### Case history

The clinical history of the haemophilic patient in whom PrP<sup>res</sup> was detected in the spleen was reviewed in detail as follows:

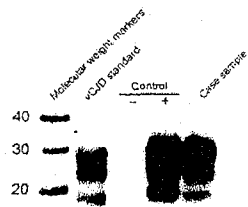


Fig. 1. Sodium phosphotungstic acid (NaPTA) precipitation/Western blotting analysis of spleen tissue samples for the presence of protease-resistant prion protein (PrP<sup>res</sup>). A sample of spleen homogenate from case 9 (case sample) corresponding to 5 mg of tissue was analysed alongside spleen samples from a control case with non-CJD neurological disease (control) corresponding to 50 mg of tissue. One of the latter control samples (+) had been spiked with an amount of variant Creutzfeldt-Jakob disease (vCJD) brain homogenate, corresponding to 300 µg of tissue, prior to NaPTA precipitation. Standard vCJD brain PrP<sup>res</sup>, corresponding to 100 µg of brain tissue, analysed without prior NaPTA precipitation, was run in the lane marked 'vCJD standard'. The molecular weight markers (in kDa) are shown in the leftmost lane.

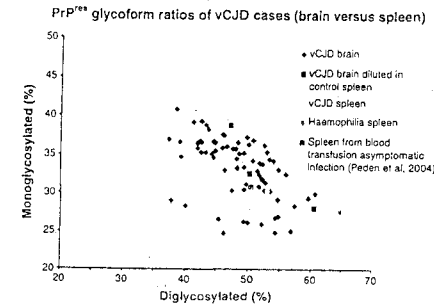


Fig. 2. Scattergram analysis of percentage diglycosylated and percentage monoglycosylated isoforms found in individual cases of variant Creutzfeldt-Jakob disease (vCJD). The glycoform ratio of protease-resistant prion protein (PrP<sup>res</sup>) following sodium phosphotungstic acid (NaPTA) precipitation in the positive spleen sample from the Haem UK study case 9 (light blue diamond) is compared with vCJD brain PrP<sup>res</sup> without NaPTA precipitation (dark blue diamonds), vCJD brain PrP<sup>res</sup> diluted in non-CJD neurological control spleen homogenate with NaPTA precipitation (red squares), endogenous vCJD spleen PrP<sup>res</sup> with NaPTA precipitation (yellow triangles). The glycoform ratio of spleen from a single case of preclinical vCJD infection following blood transfusion in an asymptomatic PRNP codon 129 MV individual (green square) is also shown.

The patient had severe haemophilia A (FVIII <1%). He was one of 10 children and all six of his affected brothers had died at an early age. He never developed antibodies to FVIII. He suffered from severe haemophilic arthropathy and despite multiple orthopaedic surgical procedures was wheelchair-bound by the age of 36 years. He also suffered from recurrent gastrointestinal (GI) bleeding and at the age of 39 sustained an intracerebral haemorrhage. He had multiple exposures to UK-sourced plasma-derived FVIII receiving 754 '500-unit' vials between 1980 and 2001 (approximately 400 000 units as the vials were overfilled). When tests became available, he was found to have both antibodies to hepatitis C and to have the virus detectable in his blood. However, his liver function tests remained normal and he did not develop any clinical signs of liver disease. He was treated with two vCJD-implicated FVIII 8Y batches in 1994 (Batch FHC 4237, 1000 units) and 1996 (Batch FHB 4547, 8025 units), the latter given over a 3-day period for a bleed into the right hip joint. Both batches included a donation from a single donor who subsequently died from vCJD in 1997.

It is also recorded that the patient had been transfused with red blood cells in 1998 (3 units), in

1999 (5 units), in 2003 (3 units) and in 2007 (3 units). The red cell transfusion in 1998 was unlikely to have been leucodepleted, but the remaining transfusions were likely to have been leucodepleted. Apart from the earlier orthopaedic procedures, the patient had undergone multiple lower GI endoscopic procedures from 1980 to 2007, with polyp resections on five occasions between 2003 and 2007; an upper GI endoscopy without biopsy was performed in 1999.

At the age of 73, he was admitted to hospital in 2008 with chest pain, having fallen out of bed 2 days previously. On examination, he was noted to be in pain with a blood pressure of 135/80 mmHg with a heart rate of 95/min. He was fully conscious (Glasgow coma scale score 15/15) and showed no evidence of cognitive impairment or any other neurological abnormalities. A 5- to 6-cm haematoma was noted over the posterior aspect of the left side of his chest. Two days later, he deteriorated suddenly with a loss of consciousness and development of hypotension. He was suspected to have sustained an intracranial haemorrhage and died the following morning. An autopsy was performed under HM Coroner's instructions, which found a thrombosed fusiform aneurysm of the left iliac artery with extension of thrombus into the lower aorta. The elbow and knee joints were swollen with evidence of previous surgery to the left knee and multiple cutaneous bruises were present over the left upper limb and left side of the trunk.

Examination of the brain revealed a cavitated old haemorrhagic infarct in the right frontal lobe, but no evidence of recent haemorrhage was noted and no histological evidence of a spongiform encephalopathy was identified. The heart, spleen, lymph nodes and appendix all appeared normal and showed no evidence of accumulation of abnormal prion protein on immunohistochemistry. The liver showed evidence of a prominent mononuclear inflammatory cell infiltrate in the portal tracts with centrilobular microvacuolation and steatosis, in keeping with the history of hepatitis C-infection. Sections of the iliac artery aneurysm showed the features of a longstanding aneurysm with a patchy infiltrate of chronic inflammatory cells in part of the wall. There was also evidence of both previous and fresh haemorrhage into the thrombus within the aneurysm, with foci of acute haemorrhage that were contiguous with foci of haemorrhage into the adjacent vessel wall. The most likely interpretation of these findings is that the patient's fall caused bleeding into the wall of the large left iliac artery aneurysm and accumulation of this haemorrhage resulted in occlusion of the vessel

with rapid propagation of blood clot upwards into the aorta resulting in hypotension, loss of consciousness and death.

Following the autopsy and with appropriate consent, frozen tissue samples from the brain, spleen and lymph node were submitted to the National CJD Surveillance Unit, along with fixed samples from the heart, liver, spleen, lymph node and appendix and iliac artery aneurysm.

## Discussion

We describe the pathological analysis of tissues from a group of 17 UK patients with haemophilia considered to be at increased risk of vCJD through exposure to UK-sourced plasma products during the period between 1980 and 2001. Eleven out of 17 patients had died, of whom six patients had previously recorded treatment with vCJD-implicated batches, including one patient who had received treatment with an implicated batch made from the same plasma pool as batch FHB 4547 (received by the index case). Another patient (not included in this study), who is still alive, has received treatment with two vCJD-implicated batches, one of which contained plasma from the donor of implicated batches FHC 4237 and FHB 4547. None of the patients in this study showed any evidence of a neurological disease consistent with vCJD. Immunohistochemistry and PET blot analysis for the abnormal form of the prion protein was consistently negative in all central and peripheral tissues examined. A single specimen from the spleen of one of these patients did, however, give a strong positive result on repeated testing for PrP<sup>Sc</sup> by Western blot analysis. The positive result had all of the expected characteristics of a true positive result in terms of the electrophoretic mobility, abundance and glycoform ratio of vCJD PrP<sup>Sc</sup>, and more specifically that of vCJD lymphoreticular tissue [6,8]; however, exhaustive re-sampling of other regions of the residual spleen tissue failed to identify any similar findings. Immunohistochemistry and PET blotting of the spleen from this case were also negative for abnormal PrP.

We therefore investigated the possibility that the positive results derived from an unexplained misidentification or contamination of samples in the laboratory. Meticulous review of the audit trail for specimen receipt, storage, sampling and analysis of this case found no opportunity for specimen misidentification, substitution or cross-contamination. Additionally, the glycoform ratio in the positive spleen sample clearly rules out sample contamination with vCJD brain, as both the abundance and

glycoform ratio are consistent with those expected from a vCJD lymphoreticular tissue [6,8]. We therefore conclude that the spleen of this case had a highly discrete positive region with readily detectable levels of PrP<sup>Sc</sup>, having a glycoform pattern typical of vCJD. In a previous report, we described the detection of PrP<sup>Sc</sup> in the spleen of another asymptomatic UK patient (who did not have haemophilia), who 5 years prior to death had received a transfusion of packed red cells from a donor who subsequently died from vCJD [8]. In this case, the levels of PrP<sup>Sc</sup> in the spleen were highly variable, with only one of the eight regions tested giving a similar result to the index case described above. Another five regions sampled gave a weak PrP<sup>Sc</sup> signal, while the remaining two regions sampled were negative. The earlier patient was also a heterozygote (methionine/valine) at codon 129 in the *PRNP* gene. However, immunohistochemistry in that case showed positive staining for abnormal prion protein in occasional follicles in the spleen, unlike the current case.

These observations together suggest that the distribution of PrP<sup>Sc</sup> in the spleen of asymptomatic patients is highly variable and that multiple samples need to be analysed to ensure (as in our current case) that false negative results are avoided. Immunoblotting for PrP<sup>Sc</sup> is more sensitive than immunohistochemistry and PET blot analysis, so it is not surprising that the immunohistochemical and PET blot findings in the current case were negative, although it should be noted that the amount of fixed tissue available for immunohistochemistry and PET blot analysis was smaller in quantity than the frozen spleen tissue for biochemical analysis. It is also conceivable that the distribution of PrP<sup>Sc</sup> in the spleen may be influenced by the *PRNP* codon 129 polymorphism, as the distribution of PrP<sup>Sc</sup> in lymphoid tissue of scrapie-affected sheep is variable between different *PRNP* genotypes [23].

The detection of PrP<sup>Sc</sup> in the spleen of this patient with haemophilia, who had no evidence of any neurological disease (including vCJD) in life, requires careful interpretation. There are four known possible routes of exposure to vCJD infection that may have resulted in this finding, namely via the food chain, transfusion with donor red cells, surgical and invasive endoscopic procedures, and finally via treatment with UK-produced FVIII, including two vCJD-implicated batches.

Dietary acquisition of vCJD infection is considered unlikely in this individual, who was aged 73 when he died, based on the observed incidence of vCJD in this age group. None of the 14 blood donors to this patient has developed vCJD, but there remains the

possibility that this group of donors could include asymptomatic carriers of vCJD infection. The investigation of patients who have also undergone endoscopy with the endoscope used on this patient has found no clinical cases of vCJD to date.

This patient's only proven link to a vCJD source is the receipt of two separate batches of FVIII, which contained plasma from a donor who subsequently developed vCJD 4.5 years after the first donation. As part of the 2004 notification exercise, the recipients of 98% of these batches have been identified and to date there have been no reports of neurological diseases (including vCJD) in this haemophilia cohort. FVIII made from another vCJD-implicated batch from the same donor was received by one of the other haemophilic patients included as an autopsy case in this study, in whom no evidence of PrP<sup>Sc</sup> was identified in the brain, spleen, tonsil or lymph node. The interval between treatment and death in that patient was 3 years shorter than that in the patient with PrP<sup>Sc</sup> detected in the spleen in this study. The vCJD donor had also made earlier blood donations; the Transfusion Medicine Epidemiology Review records one surviving recipient of non-leucodepleted red cells who is well [24]. Furthermore, there have been no reports of neurological events in patients with bleeding disorders who have received other batches of clotting factor concentrates linked to this donor.

Estimates of the relative levels of risk to which this individual was exposed, through diet, surgery/endoscopy, blood transfusion and receipt of plasma products, suggest that by far the most likely route through which this individual was infected is through receipt of UK-sourced plasma products [25] (Table 2). It is known that the individual

concerned was exposed to some 9000 units of FVIII prepared from plasma pools that included donations from a donor who went on to develop vCJD and was presumed to have been infected at the time of donation. There is no chromatographic step in the production of FVIII 8Y, which may reduce the clearance of any potential prion contamination. However, as the plasma products concerned were produced from very large pools of donors (c. 20 000), and because this individual received many units from batches not known to be implicated (c. 400 000), it is highly likely that this individual was also exposed to infectivity in presently unimplicated batches.

While there is clear evidence of the transmission of vCJD infectivity by non-leucodepleted packed red cell transfusion in humans [7–10], and transmission of scrapie and BSE by whole blood and buffy coat transfusion in sheep [26], uncertainty remains about the risk of transmission of vCJD by UK-sourced plasma. Because of this uncertainty, precautionary public health measures to prevent onward transmission of vCJD were introduced in 2004 for patients with bleeding disorders who had been treated with UK plasma-sourced products between 1980 and 2001. The current situation, with its accompanying uncertainties for the future, causes ongoing concern for these patients and their families.

## Conclusion

We believe that the findings in this case indicate vCJD infection in the spleen of this UK haemophilic patient, albeit in a very restricted distribution that may relate to the small dose of infectivity likely to

Table 2. Summary of haemophilia risk calculations assuming a population prevalence of one in 10 000.

Route	Estimated risk	Assumptions
Diet	1 in 10 000*	Background risk
Blood [12,28]	7–14 in 10 000	Assuming transmission probability is between 0.5 and 1
Endoscopy with biopsy [25,29]	1–6 in 10 000	Reduced risk based on a general surgical model (set of 20 instruments) by a factor of 10 (1 small biopsy head)
Implicated plasma products [12,25]	0.2–0.6 ID50s implies risk of 1000–3000 in 10 000	Linear dose response; the possibility of unidentified vCJD-infected donors to the plasma pools is also taken into account
Non-implicated plasma products [12,25]	>2 ID50s implies infection very likely	c. 400 000 units of factor VIII, to which unidentified vCJD-infected donors may have contributed

vCJD, variant Creutzfeldt–Jakob disease.

\*The assumed prevalence of vCJD infection in the general UK population is one in 10 000, based on an approximate average value between the results of the study by Hilton *et al.* [14] and the more recent National Tonsil Archive Study [16,17].

have been present in the UK plasma products used in treatment, and perhaps also to the heterozygous PRNP codon 129 genotype in this patient. Continuing surveillance for vCJD infection, both symptomatic (passive) and asymptomatic (active), is required to help clarify the degree of overall risk in this group of patients from treatment with UK-sourced plasma products. The findings also have implications for laboratory methodology in the proposed autopsy-based prevalence study of vCJD infection in the UK [27].

#### Acknowledgements

The UKHCDO Study is funded by the Department of Health. The National CJD Surveillance Unit is funded by the Department of Health and the Scottish Government Department of Health. We are indebted to the relatives of the patient described in the case report for giving consent for publication of this information, and to patients and their relatives who consented to entry into this study. We are grateful to Mr Graham Fairfoul and Miss Suzanne Lowrie for their scientific and technical expertise. We are grateful to the UKHCDO members who entered patients into this study, and to Dr P. Bennett and Dr J. Ball, Department of Health, for helpful discussion, to Dr S. Green, Swindon and Ms L. Dewhurst, National Haemophilia Database, Manchester, for their respective contributions.

#### Disclosures

J.W. Ironside has received financial support from Baxter US and Wyeth UK to attend two international conferences to present this work. The rest of the authors stated that they had no interests which might be perceived as posing a conflict or bias.

#### References

- Will RG, Ironside JW, Zeidler M *et al.* A new variant of Creutzfeldt-Jakob disease in the UK. *Lancet* 1996; 347: 921-5.
- Bruce ME, Will RG, Ironside JW *et al.* Transmissions to mice indicate that "new variant" CJD is caused by the BSE agent. *Nature* 1997; 389: 498-501.
- Scott MR, Will R, Ironside J *et al.* Compelling transgenic evidence for transmission of bovine spongiform encephalopathy prions to humans. *Proc Natl Acad Sci USA* 1999; 96: 15137-42.
- Ward HJ, Everington D, Cousens SN *et al.* Risk factors for variant Creutzfeldt-Jakob disease: a case-control study. *Ann Neurol* 2006; 59: 111-20.
- Bruce ME, McConnell I, Will RG, Ironside JW. Detection of variant Creutzfeldt-Jakob disease infectivity in extraneural tissues. *Lancet* 2001; 358: 208-9.

- Head MW, Ritchie D, Smith N *et al.* Peripheral tissue involvement in sporadic, iatrogenic, and variant Creutzfeldt-Jakob disease: an immunohistochemical, quantitative, and biochemical study. *Am J Pathol* 2004; 164: 143-53.
- Llewelyn CA, Hewitt PA, Knight RS *et al.* Possible transmission of variant Creutzfeldt-Jakob disease by blood transfusion. *Lancet* 2004; 363: 417-21.
- Peden AH, Head MW, Ritchie DL, Bell JE, Ironside JW. Preclinical vCJD after blood transfusion in a PRNP codon 129 heterozygous patient. *Lancet* 2004; 364: 527-9.
- Wroe SJ, Pal S, Siddique D *et al.* Clinical presentation and pre-mortem diagnosis of variant Creutzfeldt-Jakob disease associated with blood transfusion: a case report. *Lancet* 2006; 368: 2061-7.
- Health Protection Agency. Fourth case of transfusion-associated variant-CJD infection. *Health Protect Report* 2007; 1: 2-3. <http://www.hpa.org.uk/hpr/archives/2007/hpr0307.pdf>. Accessed October 16, 2009.
- Joint UKBTS/NIBSC Professional Advisory Committee Position Statement. 2007. <http://www.transfusionsguidelines.org.uk/index.aspx?Publication=DL&Section=12&Pageid=794>. Accessed October 16, 2009.
- Det Norske Veritas. *Risk of Infection From Variant CJD in Blood*. 2004. [http://www.dnv.com/news\\_events/news/2004/risk-of-infection-from-variant-cjd-in-blood.asp](http://www.dnv.com/news_events/news/2004/risk-of-infection-from-variant-cjd-in-blood.asp). Accessed 16 October 2009.
- Health Protection Agency. *Variant CJD and Plasma Products*. 2009. [http://www.hpa.org.uk/web/HPAweb/HPAwebStandard/HPAweb\\_C/1195733818681?ps=1191942152861](http://www.hpa.org.uk/web/HPAweb/HPAwebStandard/HPAweb_C/1195733818681?ps=1191942152861). Accessed 16 October 2009.
- Hilton DA, Ghani A, Conyers L *et al.* Prevalence of lymphoreticular prion protein accumulation in UK tissue samples. *J Pathol* 2004; 203: 733-9.
- Clarke P, Ghani AC. Projections of the future course of the primary vCJD epidemic in the UK: inclusion of subclinical infection and the possibility of wider genetic susceptibility. *J R Soc Interface* 2005; 2: 19-31.
- Clewley JP, Kelly CM, Andrews N *et al.* Prevalence of disease-related prion protein in anonymous tonsil specimens in Britain: cross sectional opportunistic survey. *BMJ* 2009; 338: b1442.
- Spongiform Encephalopathy Advisory Committee. *Position Statement: Prevalence of Subclinical Variant Creutzfeldt-Jakob Disease Infections*. 2008. <http://www.seac.gov.uk/statements/state-cjd-infections.pdf>. Accessed 16 October 2009.
- Head MW, Bunn TJ, Bishop MT *et al.* Prion protein heterogeneity in sporadic but not variant Creutzfeldt-Jakob disease: U.K. cases 1991-2002. *Ann Neurol* 2004; 55: 851-9.
- Wadsworth JD, Joiner S, Hill AF *et al.* Tissue distribution of protease resistant prion protein in variant Creutzfeldt-Jakob disease using a highly sensitive immunoblotting assay. *Lancet*, 2001; 358: 171-80.
- Glaziel M, Abela E, Maissen M, Aguzzi A. Extraneural pathologic prion protein in sporadic Creutzfeldt-Jakob disease. *N Engl J Med* 2003; 349: 1812-20.
- Ritchie DL, Head MW, Ironside JW. Advances in the detection of prion protein in peripheral tissues of variant Creutzfeldt-Jakob disease patients using paraffin-embedded tissue blotting. *Neuropathol Appl Neurobiol* 2004; 30: 360-8.
- Schulz-Schaeffer WJ, Tschoko S, Kranefuss N *et al.* The paraffin-embedded tissue blot detects PrP(Sc) early in the incubation time in prion diseases. *Am J Pathol* 2000; 156: 51-6.
- Jeffrey M, Begara-McGorum I, Clark S *et al.* Occurrence and distribution of infection-specific PrP in tissues of clinical scrapie cases and cull sheep from scrapie-affected farms in Scotland. *J Comp Pathol* 2002; 127: 264-73.
- Hewitt PE, Llewelyn CA, Mackenzie J, Will RG. Creutzfeldt-Jakob disease and blood transfusion: results of the UK Transfusion Medicine Epidemiological Review study. *Vox Sang* 2006; 91: 221-30.

- Bennett PG, Ball J. *vCJD Risk Assessment Calculations for a Patient With Multiple Routes of Exposure*. 2009. [http://www.dh.gov.uk/en/Publicationsandstatistics/Publications/PublicationsPolicyAndGuidance/DH\\_100357](http://www.dh.gov.uk/en/Publicationsandstatistics/Publications/PublicationsPolicyAndGuidance/DH_100357). Accessed 16 October 2009.
- Houston F, McCutcheon S, Goldmann W *et al.* Prion diseases are efficiently transmitted by blood transfusion in sheep. *Blood* 2008; 112: 4739-45.
- Health Protection Agency. *National Human Post-Mortem Tissue Archive to Study the Prevalence of Abnormal Prion Protein*. 2007. Recommendations of a Working Group. [http://www.hpa.org.uk/web/HPAwebFile/HPAweb\\_C/1240986155624](http://www.hpa.org.uk/web/HPAwebFile/HPAweb_C/1240986155624). Accessed 16 October 2009.

- Bennett PG, Dobra SA, Gronlund J. The implications for blood donors if a recipient develops variant Creutzfeldt-Jakob disease. *OR Insight* 2006; 19: 3-13.
- Department of Health. *Assessing the Risk of vCJD Transmission via Surgery: An Interim Review*. 2005. [http://www.dh.gov.uk/en/Publicationsandstatistics/Publications/PublicationsPolicyAndGuidance/DH\\_4113541](http://www.dh.gov.uk/en/Publicationsandstatistics/Publications/PublicationsPolicyAndGuidance/DH_4113541). Accessed 16 October 2009.